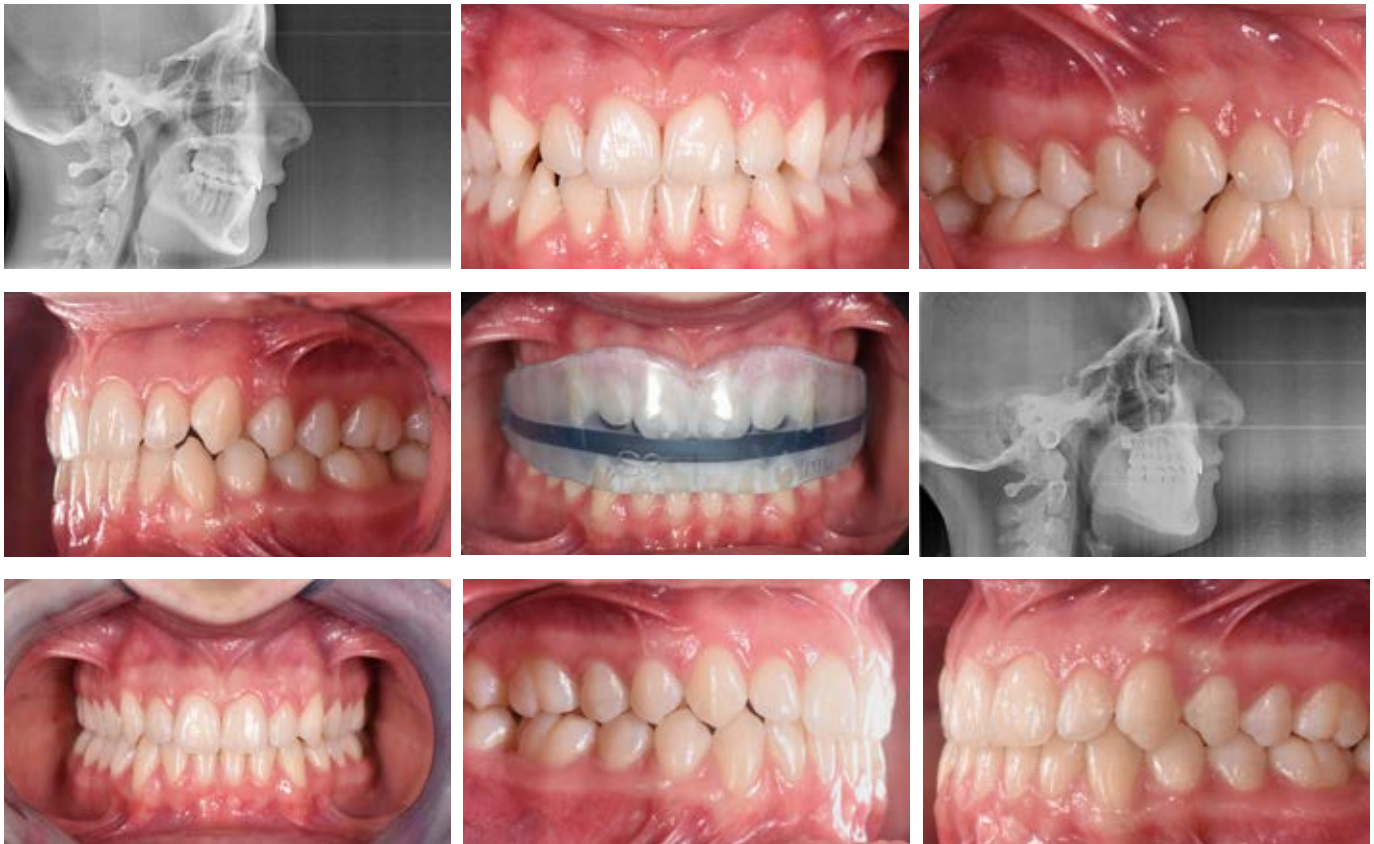


TREATED CASES • DTM APPLIANCES

Patient G.M. 16 Years old

Tendency of third class. Lack of correct intercuspitation. Atypical swallowing.



The patient was treated with A.M.C.O.P. DTM S Integral for 12 months in order to recreate functional occlusal arrangement and correct mandibular positioning .