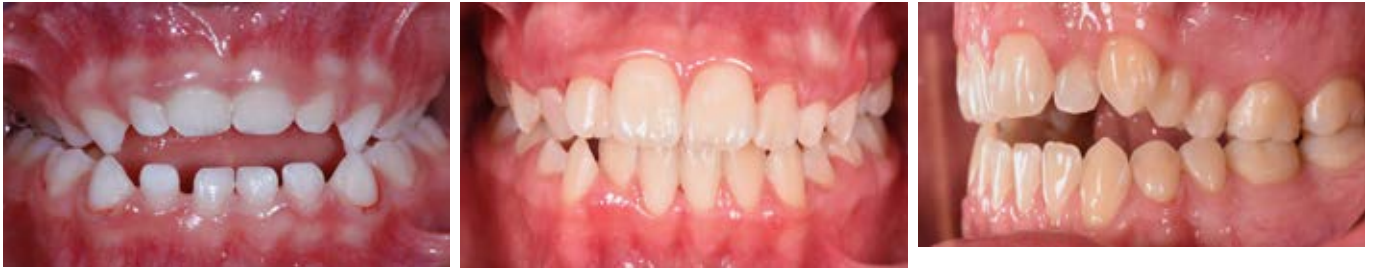

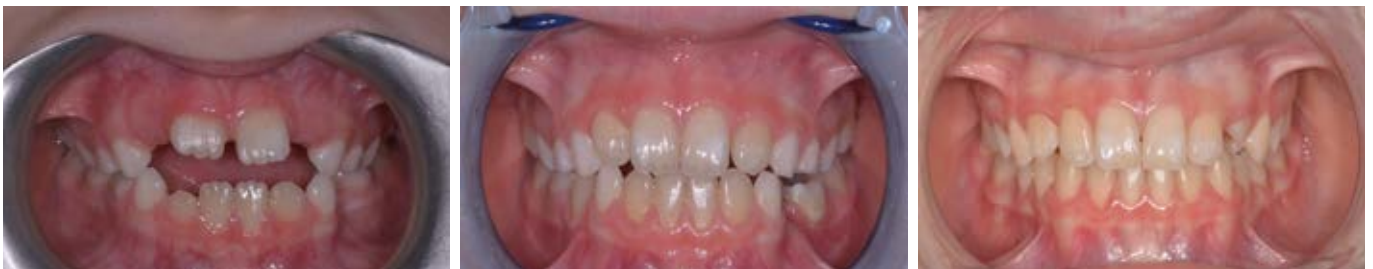## TREATED CASES • ELASTOOSAS

C.S. Patient aged 3 years, Dental Class III, Open Bite, severe upper arch contraction, bilateral Cross Bite, atypical swallowing, oral respiration, sleep disturbance, OSAS.



The present case shows a serious skeletal problem such as contraction of the upper jaw associated with atypical swallowing and difficult breathing. In these cases the appliance indicated is **ELASTOOSAS**. Its function is to expand and coordinate the upper and lower arches.

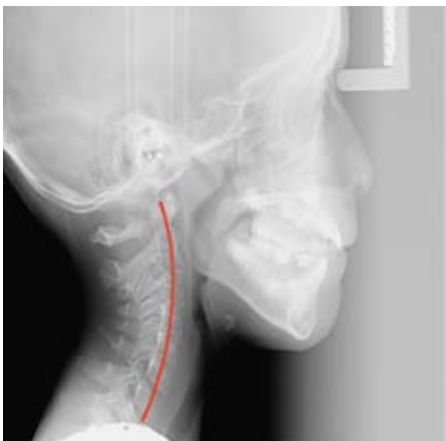
Patient aged 8 years Open skeletal and anterior dental bites, breathing difficulties (paediatric OSAS)



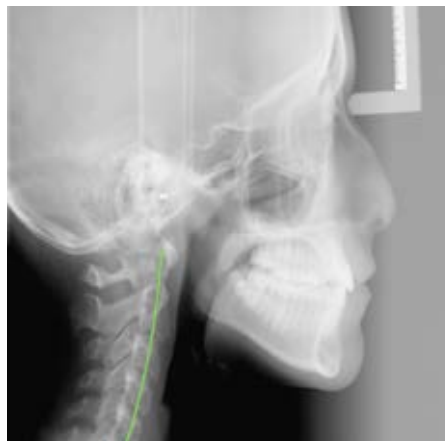Initial case

Case after 7 months

Final case after 24 months



May 2016 - Pre-treatment



November 2020 - Post treatment

Malocclusion is characterised by contraction of the upper jaw with reduced space for the eruption of permanent teeth. The therapy sequence involves the following steps:

- motivation
- speech therapy
- A.M.C.O.P. elastodontic therapy
- elastodontic restraint for about 12 months.